

# Effect Of Low Level Laser Therapy On Intra Oral Wound Healing

**Harith H Kaskos**  
BDS, MSc (Lect)

**Dept. of Oral and Maxillofacial Surgery**  
College of Dentistry, University of Mosul

**Abdull H Al-Hasan**  
BV, MSc, PhD (Asst Prof)

**Department Surgery and Theriogenology**  
College of Veterinary Medicine, University of Mosul

## الخلاصة

**أهداف الدراسة:** تهدف الدراسة الى تقييم تأثير أشعة الليزر (مستوى واطع) على الأنسجة الرخوة الفموية لاسيما وان التقييم تم باستخدام الفحص النسيجي والتحليل المختبري (C-reactive protein). **المواد وطرائق العمل:** أجريت الدراسة على الفئران المختبرية وعددها (20) وقسمت إلى مجموعتين. المجموعة الأولى وهي الضابطة وعددها (10) والمجموعة الثانية وهي الفاحصة وعددها (10). تم إجراء العملية الجراحية لكلا المجموعتين داخل الفم وذلك برفع طية كاملة للثة في منطقة الفك السفلي مقابل إلى القواطع الأمامية السفلى، ثم إعادتها بعد رفعها إلى الوضع الأصلي لها ومن ثم خياطتها جراحيا. تم تعريض المجموعة الثانية لأشعة الليزر (مستوى واطع) إلى موضع العملية الجراحية داخل الفم بجرعة 0,75 جول/سم<sup>2</sup> ولمدة 15 دقيقة لكل جلسة، بعد العملية مباشرة ومن ثم الأيام 5 و 11 و 9. تم إجراء الفحص النسيجي (أخذ عينة من النسيج الفموي المعرض إلى أشعة ليزر) للأيام 5 و 9 و 11، والفحص المختبري لـ C-reactive protein عن طريق سحب الدم من الفئران من القلب مباشرة. **النتائج:** أثبتت النتائج لفحص النسيجي بسرعة تكوين الأوعية الدموية والخلايا المكونة لألياف الكولاجين بقيمة معنوية للأيام 5 و 9 و 11 مقارنة بالمجموعة الضابطة، وأثبتت قيمة C-reactive protein ارتفاع معنوي فقط لليوم الخامس ما بعد العملية وتراجع مستوى المعنوية في اليوم السابع. **الاستنتاج:** أثبتت التجربة البحثية بان أشعة الليزر (مستوى واطع) بجرعة 0,75 جول/سم<sup>2</sup> ولمدة 15 دقيقة على الأنسجة الرخوة داخل الفم قد سرعت من التأم الجرح.

## ABSTRACT

**Aim:** To evaluate the response of intraoral soft tissue by low level laser light, histologically and biochemically. **Materials and methods:** The study was performed on (20) healthy rats. A clean two sided mucoperiosteal flap was raised opposite to the area of lower incisors. The rats were divided into two groups, ten for each. Histological specimens were taken at days 5<sup>th</sup>, 9<sup>th</sup> and 11<sup>th</sup> postoperative period. The dose of laser therapy in each session was 0.75 J/cm<sup>2</sup>. Each rat in each group received this dose daily for 11<sup>th</sup> days at an interval of 15 minutes. Histopathological analysis were made for both groups detecting number of blood vessels (neovascularization), collagen arrangements and number of fibroblasts. Biochemical analysis of C-reactive protein (CRP) was also conducted. **Results:** Laser therapy showed enhancement of neovascularization at days 5 and 9 postoperatively. While collagen arrangement showed significant changes at the 5<sup>th</sup>, 9<sup>th</sup> and 11<sup>th</sup> postoperative days. Biochemical analysis showed significant increase of CRP at the 5<sup>th</sup> postoperative day. This increase was followed by a significant decrease at the 7<sup>th</sup> postoperative day in comparison with the control group. **Conclusion:** The present results indicated that low level laser therapy at a dose of 0.75 J/cm<sup>2</sup> enhanced wound healing.

**Key words:** Soft laser, wound healing, intra oral

Kaskos HH, Al-Hasan AH. Effect Of Low Level Laser Therapy On Intra Oral Wound Healing. *Al-Rafidain Dent J.* 2011; 11(1):105-112.

*Received:* 27/5/2009

*Sent to Referees:* 4/6/2009

*Accepted for Publication:* 16/11/2009

## INTRODUCTION

Wound healing can be defined as the summation of a number of processes which follow injury including coagulation, inflammation, matrix synthesis and deposition, angiogenesis, fibroplasias, epithelization and remodeling.<sup>(1)</sup> Many methods have been advocated to promote wound healing either biological such as Larva

therapy<sup>(2)</sup>, stem cell therapy<sup>(3)</sup>, platelet rich plasma<sup>(4)</sup> and gene therapy<sup>(3)</sup>, physical such as electrical stimulation<sup>(5)</sup>, magnetic field<sup>(6)</sup>, warming<sup>(7)</sup>, miscellaneous therapies such as hyperbaric oxygen<sup>(8)</sup>, topical oxygen therapy<sup>(9)</sup> and laser or low level laser therapy<sup>(10)</sup> (LLLTL). Other names for the latter term include cold laser, soft laser, therapeutic laser and low power laser.

Laser energy is generated based on the principle of light amplification of stimulated emission of radiation. Laser has been used in several medical specialities and recently the dental profession has used laser both as a surgical tool and a biomodulating agent. Laser energy is highly coherent, polarized focused and monochromatic concentrated light which in contact with different tissues results in several effects on tissue depending upon the wave length and optical properties of irradiated tissue. LLLT has been used as an important tool for control of inflammatory process<sup>(11)</sup>. The determination the level of some serum proteins may be useful for the differentiation of inflammatory conditions as well as the clinical conditions showing an increase or decrease in the acute phase response one of which is C-reactive protein (CRP)<sup>(12)</sup>. The magnitude of CRP varies directly with the degree of tissue damage<sup>(13)</sup>. CRP plasma is usually low, increased quickly at the onset of acute inflammatory process and quickly falls when effective control of the process occurs<sup>(14)</sup>.

The mechanism of action of LLLT on the cell is briefed as that :-When the light photons are applied to the tissue ,absorption in the mitochondria and cell membrane by chromophore results in an increase in ATP synthesis ( $Ca^{+2}$  and respiratory chain involved )with formation of a low amount ROS of (Reactive O<sub>2</sub> species like H<sub>2</sub>O<sub>2</sub>.) .DNA,RNA protein synthesis is increased as well as mitosis and cellular proliferation resulting in rapid tissue healing and pain control.<sup>(15,16)</sup> Since cell proliferation is one of the basic manifestations of any living organism, many authors through experimental studies confirmed that LLLT stimulate cell and fibroblast proliferation , increased the mean blood vessel sections on day 7 healing period of third degree burns in a histopathological study on rats<sup>(17,18,19)</sup>. Non-invasive, low-power lasers with an output up to 500 mW have been reported to have stimulatory, anti inflammatory and analgesic effects<sup>(20)</sup>.

## MATERIALS AND METHODS

Twenty healthy rats of both sex were enrolled in the experiment. The rats were

placed in cages and received basal diet and tap water. The weight of each rat ranged from (250-350 gs), aged 3-5 months .They were divided randomly into two groups,

### 1-Control group:

The rats in this group were (10) that underwent an oral surgical procedure without postoperative laser irradiation.

### 2-Experimental group:

The rats in this group were (10) that underwent an oral surgical procedure with scheduled laser irradiation.

### Anesthesia of animal:

The experimental rats were anaesthetized by using a combination of Ketamine and Xylazine at adose of 80mg/kg and 10mg/kg respectively by intramuscular injection in the thigh muscle. The duration of anesthesia was about 45 minutes.

### Surgical procedure:

The surgical field sterilized by iodine solution (2%). A two sided intra-oral buccal mucoperiosteal flap was designed opposite to the area of present lower incisors using a Bard parker Scalpel handle (No 3) with a No 15 blade mounted on it, flap was reflected by atissue dissector and repositioned after it was irrigated with sterile normal saline solution 0.9% (Alnasser-pharmaceutical chemicals. Co, Egypt) and sutured with 3/0 black silk suture (Kangyou Medical Instrument Co, China),one stitch in each vertical relaxed incision.

### Laser system:

The laser system used in this experimental study was made by Space Laser Corporation, Italy as shown in Figure(1),with He-Ne radiation only. Its characteristics are as follows: laser system class IV, He-Ne output power 0.006mW, He-Ne wave length 632.8nm.



Figure (1): Laser device

*Animal irradiation:*

After completion of the surgical procedure, the experimental animal was placed 30 cm away from the source of laser beam according to the manufacturers instruction with the beam directed perpendicular to the wound site as shown in Figure (2).The first session began directly after finishing the surgical operation and then continued daily till day 11. Each session was for 15 minutes. As the power of He-Ne laser of the device is 0.006mW and the surface area of exposure is 12 cm<sup>2</sup>, so the energy density (Dose) for each session was: 0.006mW\*15 minutes\*60 sec/ 12 cm<sup>2</sup> = 0.75 J/cm<sup>2</sup>.

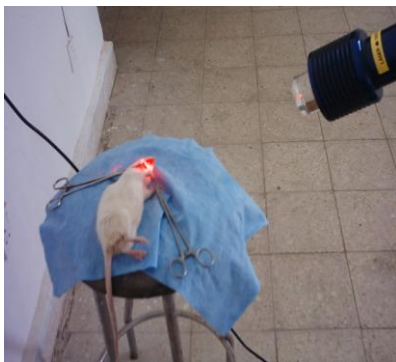


Figure (2): Animal irradiation 30 cm away from laser beam

*Blood sampling:*

A blood sample was taken directly from the heart (1ml) of rats who were sacrificed at experimental days (5 -9 -11) respectively for serological analysis of CRP. Biopsy was taken from the intraoral soft tissue that was raised and reflected for histological sectioning. NO systemic Antibiotic or other medications was given for both experimental and control group which might affect the inflammatory process.

Table (1): C-reactive protein CRP of postoperative days

Postoperative days	Group tested	Mean mg/l	SE
Day 5	Control	280.000*	30.0
	Experimental	180.000	24.0
Day 9	Control	70.4 **	8.9
	Experimental	320.4	60.5

\*Significant p<0.05. \*\*very reduced ,Significant ; p<0.00.

*Histopathological analysis:*

1-At day5 (control group) if- fuse extensive mononuclear(lymphocyte,

*Materials used for serological test:*

The CRP kit includes CRP negative control, CRP positive control, CRP latex reagent,Standared company,Spain plane tube .Disposable plastic syringe 1 ML Af-ma-dispo, Jordon.

Histological evaluation included the following:-

- 1- Neovascularization :(It was made by counting the number of blood vessel per square at magnification of 10X. Each field was selected randomly).
- 2- Fibroblast number(fibroplasia): (It was made by examining 5 locations selected randomly in each slide by counting the number of inflammatory cells within the indicating square at a power field of 10X).
- 3- Collagen arrangement (it was made by observing the collagen arrangement at 10Xpower field in all over the wound area and as follows based on the scoring system reported in Yu et al)<sup>(21)</sup>.  
0=None to sparse amount at edge.  
1=Thin layer at edge.  
2= Thin layer across wound.  
3= Uniformly thick.

The Student T- test was used for statistical comparison between experimental and control groups.

**RESULTS**

*CRP analysis:*

At day 5, the serum concentration of C-reactive protein (CRP) for the laser treated group increased significantly(p<0,05) as compared to control group. At day 9 post operatively, the CRP concentration decreased significantly( p<0.001) as compared to control .The results are shown in Table (1).

macrophage)visualized along the edge of wound with very small newly(more numbers) formed blood vessels .

The collagen density and arrangement were poor, little number of fibroblasts spread along with collagen fibers . The results are shown in Figure (3).

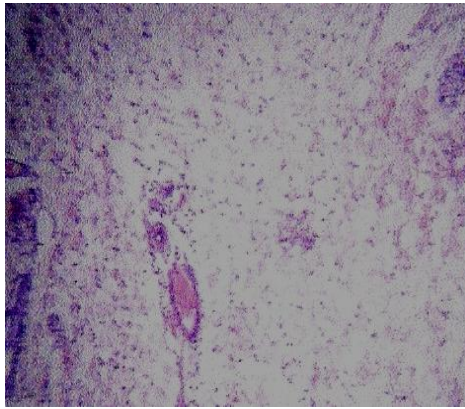
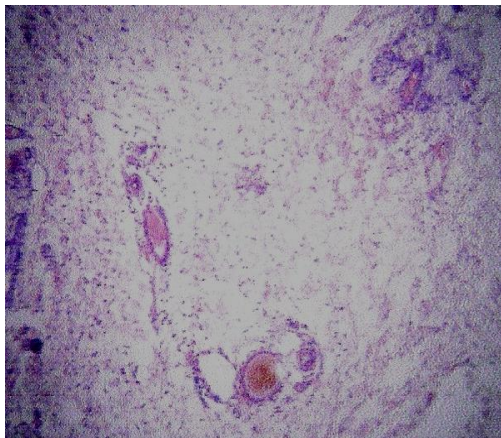


Figure (3): Normal vascularisation at day 5 without laser application.

*2-At day 5 (experimental group)*

There was extensive vascularisation ,better collagen arrangement in addition to more extensive fibroplasia in comparison to the control wound. The results as shown in Figure (4).



Figure(4): New vascularisation at day 5 with laser application.

*3-At day 9 (control group)*

The wound line was filled with dense mature granulation tissue infiltrated by mononuclear inflammatory cells .The results are shown in Figure (5).

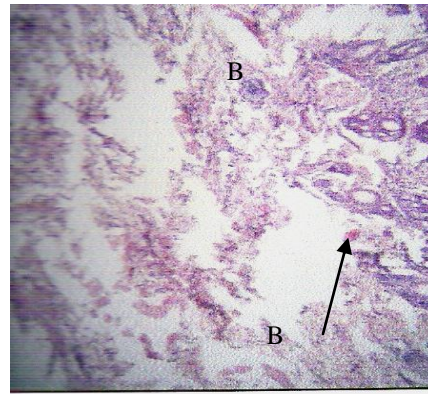


Figure (5): Normal vascularisation **B**, Fibroplasia,at day 9 postoperatively without laser application .

*4-At day 9 (experimental group):-*

Similar histopathological changes were seen in the experimental wound at the same period . The results are shown in Figure (6).

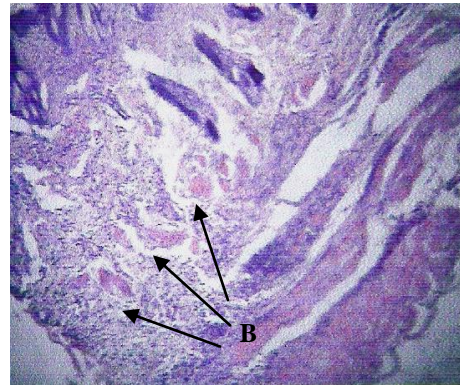


Figure (6): Increased vascularisation **B**,Fibroplasia at day 9 postoperatively with laser application

*5-At day 11 (control group)*

Dense and mature granulation tissue was observed. The results are shown in Figure(7).

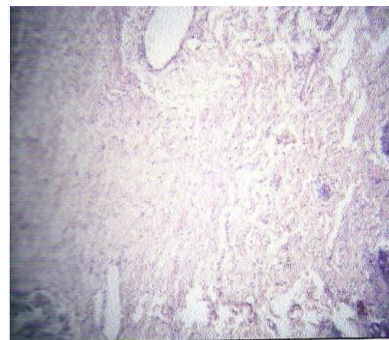


Figure (7): Normal healing process with normal fibroblast infiltration at day 11 postoperatively without laser application.  
*6-At day 11<sup>th</sup> (experimental group)*

The healing process was more completed than the control group, with more fibrous tissue. The results are shown in Fig(8)  
 Statistical analysis: - are  
 At day 5\* Statistical comparison between

the experimental and control group showed that revascularization, collagen arrangement and number of fibroblast were highly significant (P<0.01) Table(2).

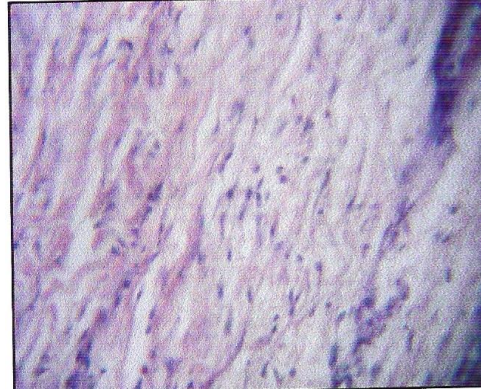


Figure (8): Dense granulation tissue with severely increased in fibroblast at 11 postoperative day with laser irradiation.

Table (2): Histological finding at day 5 postoperatively

Groups	Mean number of vessel +SE	Mean number of collagen arrangement +SE	Mean number of fibroblast cells +SE
Control	15.6 + 1.8*	1.8 + 0.19*	9.89 + 1.66*
Experimental	7.5 + 0.7	0.6 + 0.22	3.79 + 0.59

\* Significant p<0.001

*Histopathological analysis:*

1-At day5 (control group) Dif- fuse extensive mononuclear (lymphocyte,macrophage) visualized along the edge of wound with very small new-

ly(more numbers) formed blood vessels.

The collagen density and arrangement were poor, little number of fibroblasts spread along with collagen fibers . The results are shown in Figure(3).

Table (3): Histological finding at day 9 postoperatively

Groups	Mean number of vessel +SE	Mean number of collagen arrangement +SE	Mean number of fibroblast cells +SE
Control	10.8 + 1.0*	2.2 + 0.2**	6.9 + 0.69*
Experimental	7.0 + 0.3	1.6 + 0.3	4.0 + 0.29

\* Significant p<0.05, \*\* Non Significant p>0.05

2-At day 5 (experimental group)

There was extensive vascularisation ,better collagen arrangement in addition to

more extensive fibroplasia in comparison to the control wound. The results as shown in Figure (4).

Table (4): Histological finding at day 11 postoperatively

Groups	Mean number of vessel +SE	Mean number of collagen arrangement +SE	Mean number of fibroblast cells +SE
Control	7.3 +0.4**	2.7 + 0.2**	9.89 + 1.66*
Experimental	5.9 + 0.4	1.9 + 0.3	3.4 + 0.7

\* Significant  $p < 0.05$ , \*\* Non Significant  $p > 0.05$

### 3-At day 9 (control group)

The wound line was filled with dense mature granulation tissue infiltrated by mononuclear inflammatory cells. The results are shown in Figure(5).

### 4-At day 9 (experimental group):-

Similar histopathological changes were seen in the experimental wound at the same period. The results are shown in Figure(6)

### 5-At day 11 (control group)

Dense and mature granulation tissue was observed. The results are shown in Fig(7)

### 6-At day 11<sup>th</sup> (experimental group)

The healing process was more completed than the control group, with more fibrous tissue. The results are shown in Figure(8)

Statistical analysis :- are

At day 5<sup>th</sup> Statistical comparison between the experimental and control group showed that revascularization, collagen arrangement and number of fibroblast were highly significant ( $P < 0.01$ ) Table(2). At day 9<sup>th</sup> Statistical comparison showed a significant increase in neo vascularisation ( $P < 0/05$ ) but with no significant differences in collagen arrangement \between experimental and control group. A Significant increase in the number of fibroblast in the experimental group was observed with the control group ( $P < 0.001$ ). This is shown in Table(3).

At day 11<sup>th</sup> Statistical comparison showed a highly significant reduction in the number of inflammatory cell infiltration and a significant increase in the number of fibroblast in the experimental group compared with the control group.

There were no significant ( $P > 0.05$ ) differences in the number of blood vessels and collagen in the experimental wound compared with the control one this is shown in Table (4).

## DISCUSSION

Low level laser therapy (LLLT) is recognized as an effective therapeutic method in improving tissue healing by enhancing collagen synthesis as that suggested in many studies in vivo and vitro by promoting the transformation of fibroblasts to myofibroblast<sup>(21)</sup>. In the present study, serological and histopathological changes were conducted at subsequent days (5 and 11 days) postoperatively to evaluate the inflammatory phase and proliferative phase of wound healing. CRP (C-reactive protein) level was highly significant at day 5 postoperatively. This only means that laser light doesn't exacerbate the inflammatory process (prostaglandineE2 is an important chemical mediator in inflammatory process) but rather condenses the time frame from onset to resolution through an acceleration of the process. A active LLLT reduced prostaglandineE2 concentration as compared with the concentration before the treatment<sup>(22)</sup>.

### Evaluation of neovascularisation:

The significant increase of neovascularisation at days 5 and 9 postoperatively was due to an increase in the production of many angiogenic factors like that released from macrophages. These factors have been detected after laser irradiation<sup>(23)</sup>.

### Evaluation of fibroblast cells number (fibroplasia):

There was significant increase in fibroblast numbers at days 5, 9 and 11. The fibroblast became the prominent cell type at day 5 in clean non infected wounds<sup>(24)</sup>. This may explain that a significant increase at days 5 and 9 postoperatively was noticed and only significant at day 11 where granulation tissue progressed to cellular fibrous tissue. The re-

searcher found that LLLT can increase the proliferative rate of human fibroblast<sup>(25)</sup>.

*Evaluation of collagen arrangement:*

The better and highly significant collagen arrangement at day 5 postoperative period in the experimental group but with not significance at day 9 and 11 subsequent days came in agreement with researchers<sup>(26,27,28)</sup>

**CONCLUSION**

The study concluded that LLLT when used at a dose of 0.75 J/cm<sup>2</sup> at adjusted time intervals enhanced wound healing by primary intention.

**REFERENCES**

1. Russell RC, Williams NS, Bulstrode MA. Bailey and love's Short Practice of Surgery. 23<sup>rd</sup> ed. Arnold. New York, USA, 2000, Pp:29-40.
2. Kumar S, Wong PF, Leaper DJ. What is new in wound healing? *Turk J Med Sci.* 2004; 34:147-160.
3. Falanga V, Advanced treatment for non-healing chronic wound. *EWMA Journal.* 2004; 4(2):4-6
4. Marx RE, Garg AK. Dental and Cranio-Facial Applications of Platelets Rich Plasma .Quintessence Publishing, Philadelphia ,USA. 2005: Pp:5-20.
5. Sussman C, Jensen BM. Wound care .A collaborative practice manual for physical therapists and nurse. Aspen. *Gainthersberg ,Maryland Australia.* 1998; Pp: 357-385,389-401.
6. Marcov MS. How to go for magnetic field therapy. *J Back musculoskeletal Rehabilitation.* 2003;18:17-29.
7. Kumar S, Wong PF, Melling AC, Leaper DJ. Effect of preoperative hypothermia and warming in surgical practice. *Int Wound J.* 2005; 2(3):193-204.
8. Shakey LS. Current Indications to Laser Physics . Springer- Verlage.USA. 2000; Pp: 1-20.
9. Sen CK. The general case for redox control of wound repair . *Wound Repair Regen.* 2003;11(2): 313-321.
10. Hawkins D, Houreld N, Abrahamse H. low level laser therapy (LLLT) as an effective therapeutic modality for delayed wound healing. *Ann N Y Acad Sci.* 2005; 1056:486-493.
11. Sutter R, Grossenbacher R. Reception of palatal tumor with CO2 laser. *J laryngol otology;* 1990; 4:20-23.
12. Freitas AC, Barbosa AL, Miranda P, Thiers FA, Vieira AL. Assessment of anti inflammatory effect of 830nm laser light using c-reactive protein levels. *Barz Dent J.* 2001; (12)3:187-190.
13. Crockson RA, Payne CJ, Ratcliff RA, Smoothill JF. Time sequence of acute phase reactive proteins following surgical trauma. *Clin Chrin Acta.* 1966; 14:435-441.
14. Shih LY, WU JJ, Yang DJ. Erythrocyte sedimentation rate and c-reactive protein value in patient with total hip arthroplasty .*Clin Orthop Relat Res.* 1987; 225: 238-246.
15. Gonçalves WLS, FM Souza, JP Cirque, JG Ppires, Moysés MR. Influence of He-Ne laser therapy on the dynamics of wound healing in mice treated with anti-inflammatory drugs. *Braz J Med Biological Research.* 2007; 40: 877-884.
16. Michael R. Hamblin, Ronald W. Waynant, Juanita Anders Mechanisms of Low Level Light Therapy. *Proc of SPIE.* 2006; Vol. 6140.
17. Mirzaei M, Bayat M, Mosafa N, Mohsenifar Z, Piryaei A, Farokhi B, Rezaei F, Sadeghi Y, Rakhshan M, Effect of low-level laser therapy on skin fibroblasts of streptozotocin-diabetic rats. *Photo med Laser Surg.* 2007; 25(6):519-25
18. Koutna M, Janisch R, Veselska R. Effects of low-power laser irradiation on cell proliferation . *Scripta Medica (BRNO)* 2003;76 (3): 163-172.
19. Bayat M , Vasheghani MM, Razavi N. Effect of low level helium-neon laser therapy on the healing of third degree burns in rats. *J Photo Chem Photo Biol B.* 2006, 1;83(2):87-93.
20. Kert J, Rose L. Clinical laser therapy. Low level laser therapy. Scandinavian Medical Laser Technology, Veksoe, 1989.
21. Gonçalves WLS, Souza FM, Conti CL. Cirqueira JP, Rocha WA, Pires JGP, Barrosand LAP, Moysés MR. Influence of He-Ne laser therapy on the dynamics of wound healing in mice treated with anti-inflammatory drugs. Topical laser irradiation and wound healing. *Braz J Med Biological Research* 2007,40: 877-884.
22. Bjordal JM, Martins RA, Iversen VV. Arandomized, placebo controlled trial of

- low level laser therapy for activated A chilled tendonitis with microdialysis measurement of peritendinous prostaglandin E2 concentrations. *Br J Sports Med.* 2006,40:76-80.
23. Kipshidze N, Nikolaychi KV, Keelan MH. Low -power helium-neon laser irradiation enhances production of vascular endothelial factor and promotes growth of endothelial cells in vitro. *Laser Surg Med.* 2001,28:355-364.
24. Snezana pesevska, Marija Nakova, Ana pejcic, Kiro ivanovski, Nikola Angelov, Sonja Mindova. Biostimulative laser therapy. Base for favorized and accented results in dentistry. *Acta Facmed Naiss.* 2006,23(1):75-78.
25. Lorenz HP, Longaker MT. Wound biology, pathology-and Management. Elsevier Science Limited. Philadelphia, USA. 2004; Pp:77-88.
26. Yu W, Naim JO, Lazafame RJ. Effect of photostimulation on wound healing in diabetic mice. *Laser Surg Med.* 1997; 20:56-63.
27. Junior AM, Oliveira RG, Farias RE, Andrade LC, Aarestrup FM, Modulation of fibroblast proliferation and inflammatory responses by low intensity laser therapy in tissue repair process. *An Bras Dermatol.* 2006; 81(2):150-156.
28. Mohammad A Mohammad Al-Saigh: An Evaluation of low intensity Helium-Neon laser in facial skin wound healing by primary intention An experimental study, Thesis College of Dentistry university of mousl-Iraq, 2007.